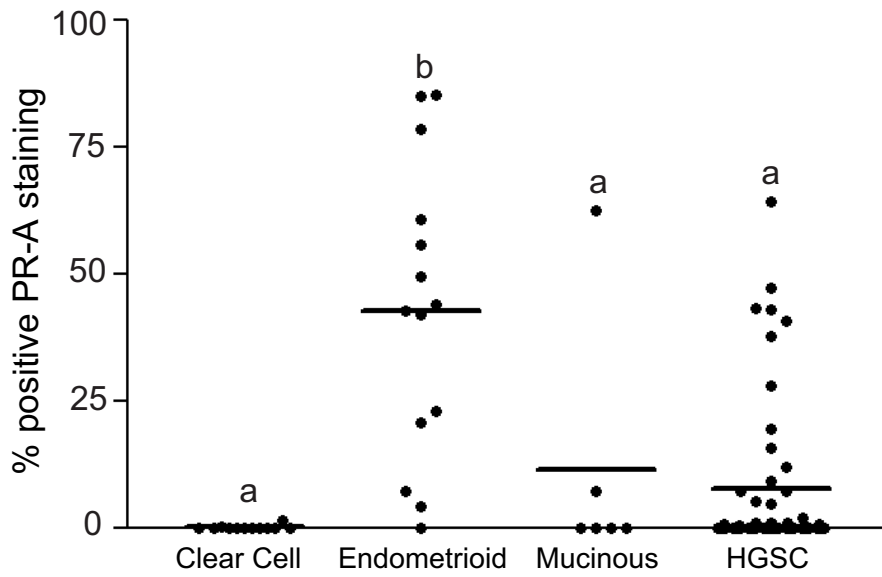


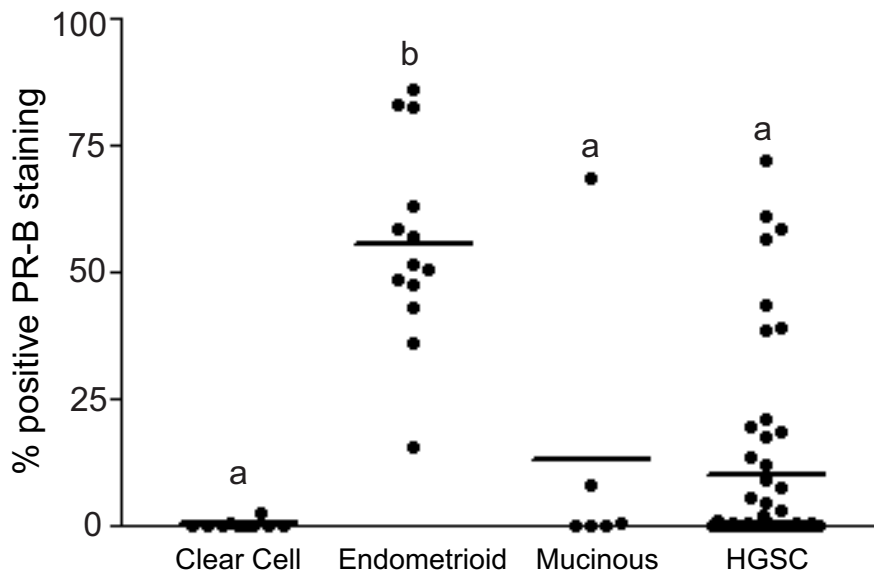
Supplemental Figure 3. Expression of PR-A and PR-B in Ovarian Carcinoma Histotypes.

A.



	Clear Cell	Endometrioid	Mucinous	HGSC
total n	12	14	6	51
no. cases with >10% positivity	0 (0%)	11 (79%)	1 (17%)	10 (20%)

B.



	Clear Cell	Endometrioid	Mucinous	HGSC
total n	10*	13*	6	51
no. cases with >10% positivity	0 (0%)	13 (100%)	1 (17%)	13 (25%)